

Chronic Hepatotoxicity and Nephrotoxicity Study of Orally Administered Aqueous and Ethanolic Extracts of *Carica papaya* Seeds in Adult Wistar Rats

¹Umana Uduak, ¹J.A. Timbuak, ¹S.A. Musa, ¹W.O. Hamman, ¹Samuel Asala,

²Joseph Hambolu and ³J.A. Anuka

¹Department of Human Anatomy,

²Department of Veterinary Anatomy,

³Department of Pharmacology, Ahmadu Bello University, Zaria, Nigeria

Abstract: About 80% of the population in many third world countries still use traditional medicine (medicinal plants) as the sole means of therapy against diseases. *Carica papaya* is a medicinal plant which has been proven to contain substances that can be used for such purposes. Some of its uses include anti-ulcerogenic, anti-fungal, anti-microbial, anti-tumour and it is employed in wound-healing activity and antifertility activity to mention a few. This study was designed to evaluate the chronic hepatotoxic and nephrotoxic effects of orally administered aqueous and ethanolic extracts of *Carica papaya* seed in adult Wistar rat. The up-and-down method as outlined in the OECD guidelines was used to determine the LD50. Twenty five adult Wistar rats weighing between 160-220 gm were used for the study. They were randomised and five assigned to each of the treatment groups. Group one was the control, group two and three received 100 mg/kg and 1000 mg/kg body weight of aqueous extract respectively while groups four and five received 100 mg/kg and 1000 mg/kg body weight of ethanolic extract respectively. They were all dosed orally for 60 days. The results of the haematological indices, renal function test and liver function test for both extracts were normal and so also were the organ body weight ratios. The histological studies of the liver, kidneys and spleen did not reveal any pathologic changes when compared to the control group. In Conclusion it can be said that aqueous and ethanolic extracts of *Carica papaya* seed extract is not hepatotoxic and nephrotoxic to adult Wistar rats.

Keywords: *Carica papaya*, chronic, histological studies, kidney, liver and spleen

INTRODUCTION

According to the world health organization, about 80% of the population in many third world countries still use traditional medicine (medicinal plants) for their primary health care due to poverty and lack of access to modern medicine (Silva, 1997). The World Health Organisation (WHO) therefore approved the use of herbal products for national policies and drug regulatory measures in order to strengthen research and evaluation of the safety and efficacy of these products (Saxena, 2001). Farnsworth and his co-worker in 1985 reported that of the 119 plant derived drugs listed by WHO study, 74% were discovered as a result of chemical studies to isolate the active compounds responsible for the use of original plant in traditional medicine (Farnsworth *et al.*, 1985). *Carica papaya* (Pawpaw) is a tree like herbaceous plant in the family *caricaceae*. It is cultivated mainly for their ripe fruit used as breakfast fruit and as an ingredient in jellies. *Carica papaya* is a medicinal plant in that it contains substances that can be used for therapeutic purposes. These substances are precursors for chemo

pharmaceutical synthesis as such this plant has been used traditionally in cases of kidney failure, low sperm count, dental care, heart problems, natural memory enhancer and remedy for fibroids in uterus (Krishna *et al.*, 2008). This plant has also been recommended as an anti-ulcerogenic, anti-amoebic, anti-fungal, anti-microbial, anti-tumour, hypolipidaemic and employ in wound-healing activity, free radical scavenging activity, diuretic activity, uterotonic activity and antifertility activity (Krishna *et al.*, 2008). In addition, the powdered seeds of *Carica papaya* have other numerous applications worldwide, some includes its use in Northern India as an antihelminthic and their extracts are also used as anti-inflammatory and analgesic agents (Villegas, 1997). *Carica papaya* seeds are also said to possess antimicrobial properties (Nester *et al.*, 1998). Some other uses of *Carica papaya* includes, for example, the use of dead leaves of *Carica papaya* that fall off the tree as abortifacient (Sofowora, 1985). *Carica papaya* seed extract is currently being marketed as a nutritional supplement with purported ability "to rejuvenate the body condition and to increase energy". According to Mojica-Henshaw *et al.* (2003),

the product is said to improve immunity against common infection and body functioning. With all the uses and claims of efficacy of the seeds derivatives in treatment of the numerous ailments, it is necessary to study the effects on the blood, liver and kidneys which are the most commonly affected organs following ingestion of xenobiotics.

MATERIALS AND METHODS

Experimental animals: A total of sixty healthy, adult Wistar rats weighing 160-220 gm were acclimatised to the laboratory conditions for 7 days prior to the experiment. Ten animals were used for LD50 while twenty five each were used for acute and chronic studies. The animals were bred and housed in polypropylene cages in the animal house of the Department of Human Anatomy, Ahmadu Bello University, Zaria-Nigeria. The animals were fed rat pellet diet and layers mash, exposed to approximately 12 h light: 12 h dark cycle and water was provided *ad libitum*. Animals were treated humanely; Veterinary care and supervision were provided throughout the period of study.

Phytochemical screening tests: Desirable amount of *Carica papaya* extract was used for phytochemical tests. The extract solution was tested for alkaloids, glycosides, flavonoids, saponins, sugars and tannins according to the protocol described by Trease and Evans (1989).

Extract preparation: Ripe *C. papaya* fruits of Homestead variety were obtained from a local market in Zaria, Kaduna State between the months of November and December and authenticated at the Department of Biological Sciences, Ahmadu Bello University, Zaria Nigeria. The voucher number 0911 was obtained. The seeds were removed, air dried under shade and coarsely powdered. 200 g each of the powdered material was used for extraction. They were soxhleted with ethanol and distilled water, respectively in the Department of Pharmacognosy and Drug Development of Ahmadu Bello University, Zaria. The soxhleted material was concentrated under reduced pressure and the obtained residues were weighed to calculate the yield and the obtained extracts were used for the study.

Acute oral toxicity studies (LD50): The up-and-down method as outlined in the OECD, 2001 guideline for testing of chemicals was used for the acute oral toxicity study. The animals were randomly selected, marked for permit individual identification. They were aged between 8 and 12 weeks and the weights of those used were kept within an interval of 20% of the mean weight of any previously dosed animals. Five nulliparous, non-pregnant female Wistar rats weighing between 165-190 grams were used for each extract. The animal were fasted (only food was withheld) for 12 h and weighed

prior to dosing. Varying single doses of the *Carica papaya* extracts was administered orally using intubation cannula to one animal at a time and food withheld for another 4 h after dosing. The dosing was initiated at 175 mg/kg a 3.2 progression factor was used and the subsequent doses were 550 and 2000 mg/kg. The limit was set at 2000 mg/Kg and dosing was stopped after 3 animals survived. This procedure was done for both extracts. After each dose, the animals were observed for 14 days and the toxicity signs checked out included changes in skin and fur, eyes, mucus membranes, tremors, convulsion, salivation, diarrhea, lethargy, sleep and coma (OECD, 2003).

Chronic studies: Twenty five adult Wistar rats weighing 160-220gm were randomised and 5 assigned to each of the treatment groups. Group one was the control and received 2 mL/100 g body weight of normal saline with 2% Tween 80, group 2 and 3 had 100 mg and 1000 mg/kg body weight of aqueous extract respectively while Groups 4 and five 5 had 100 mg and 1000 mg/Kg body weight of ethanolic extract, respectively. The chronic lasted 60 days. The test substances were dissolved in a suitable vehicle that is aqueous in distilled water and ethanolic extract in 2% tween 80. After treatment the rats were sacrificed and the blood obtained for haematological indices and biochemical analysis for liver and renal function test. The tissues i.e., liver, kidneys and spleen were carefully dissected out, cleaned of any fats and weighed (absolute weight). The Relative Organ Weight (ROW) of each organ was then calculated according to the following equation:

$$\text{ROW} = \frac{\text{Absolute organ weight}}{\text{Body weight of rat (g)}} = (\text{g}) \times 100$$

The harvested tissues were fixed in 10% formal saline for routine histological processing and stained with haematoxylin and eosin.

Statistical analysis: The data obtained from the studies are represented as Mean \pm SEM. The data for acute and chronic Hepatotoxic and Nephrotoxic effects of orally administered extracts of *Carica papaya* seed extract in adult Wistar rat model were analyzed by One Way Analysis Of Variance (ANOVA), 'p' value less than 0.05 was considered as statistically significant. EZAnalyze 3.0 and Microsoft Excel 2007 were used for analysis and production of charts.

RESULTS

Phytochemical screening tests: The yields obtained were 7.8% for aqueous extract and 7% for ethanol extract. The results of phytochemical screening of aqueous and ethanolic extracts of *Carica papaya* revealed the presence of saponins, alkaloids, tannins,

Table 1: Phytochemical components seed extracts of *Carica papaya* Linn

Compounds Extracts	Saponin	Alkaloids	Tannins	Glycosides	Flavonoids	Reducing sugars
Aqueous extract	+	+	+	-	+	+
Ethanol extract	-	+	+	-	+	-

Table 2: Mean difference in body weight of Wistar rats after 60 days of *C. papaya* seed extracts administration

Groups parameters	I Control N/saline 2% Tween80	II Aqueous 100 mg/kg	III Aqueous 1000 mg/kg	IV Ethanolic 100mg/kg	V Ethanolic 1000mg/kg
Weight before	192.4±12.90	192.2±7.36	192.4±5.59	190.8±8.44	190.8±8.58
Weight after	224.2±14.74	225.4±6.54	225.2±7.95	222.8±10.04	222±6.78
Mean difference	31.80±1.59	33.20±1.02	32.80±1.24	31.00±0.78	31.80±1.50
Mean difference/100 g	17.04±.76	17.31±.72	16.40±1.01	16.46±0.84	16.54±0.709

N per group = 5; Data expressed as Mean±SEM

Table 3: Mean organ body weight of liver, spleen and kidneys of wistar rats after 60 days of *C. papaya* seed extracts administration

Groups parameters	I Control N/saline 2% Tween80	II Aqueous 100mg/kg	III Aqueous 1000mg/kg	IV Ethanolic 100mg/kg	V Ethanolic 1000mg/kg
Liver (g/100)	5.48±0.075	5.76±0.087	5.63±0.042	5.70±0.047	5.58±0.70
Spleen (g/100)	0.58±0.014	0.60±0.021	0.60±0.008	0.57±0.008	0.57±0.018
Kidney (g/100)	0.87±0.017	0.83±0.016	0.85±0.020	0.85±0.013	0.85±0.020

N per group = 5; Data expressed as Mean±SEM

Table 4: Mean haematological indices of male wistar rats after 60 days of *C. papaya* seed extracts administration

Groups parameters	I Control N/saline 2% Tween80	II Aqueous 100mg/kg	III Aqueous 1000mg/kg	IV Ethanolic 100mg/kg	V Ethanolic 1000mg/kg
WBC (x10 ³ /mm ³)	6.68±0.21	7.0±0.26	6.8±0.46	6.6±0.44	7.12±0.14
PCV (%)	39.0±0.84	38.8±0.58	38.6±1.12	37.8±.86	37.2±0.86
HB (g/100 mL)	12.96±0.26	12.9±0.20	12.88±0.36	12.58±0.30	12.56±0.38
Neutrophil(%)	29.8±1.46	28.8±1.89	29.4±2.58	27.6±2.42	29.0±2.67
Lymphocyte(%)	65.6±1.36	67.8±1.74	66.2±2.75	69.6±2.13	69.8±0.58
Eosinophil(%)	2.6±0.51	2.6±0.51	3.4±0.40	2.4±0.51	2.6±0.4
Monocyte(%)	1.40±0.40	1.4±0.40	1.6±0.25	1.4±0.25	1.4±0.25

N per group = 5; Data expressed as Mean±SEM

flavonoids and reducing sugars in the different extracts (Table 1). None of the extracts contained glycosides.

Acute oral toxicity studies (LD50): No mortality or morbidity was recorded in any of the animals used throughout the 14-day observation period following the oral administration of the different doses of the aqueous and ethanolic extracts of *C. papaya* seeds. There was no significant loss of fur and skin lesions. Nose and eyes appeared clear and normal. There was no diarrhoea, convulsion, salivation, tremors, lethargy, sleep or coma which are signs associated with oral toxicity. Animals did not show any sign of aggression or unusual behaviour during handling. The LD50 of the aqueous and ethanolic extract of *C. Papaya* seed was found to be above 2000 mg/kg.

Chronic oral toxicity: During the 60-day oral administration of both extracts of *C. Papaya* seed, no mortalities were recorded in the groups. There was no morbidity evident in all the treated animals throughout the period of administration. There were no significant signs associated with oral toxicity. Animals did not show any sign of aggression or unusual behaviour during handling.

Organ Body Weight Ratio After 60 Days Extract Administration: After 60 days of daily oral administration of the aqueous and ethanolic extracts of

C. papaya, there was general increase in body weight in all the groups as illustrated in Table 2. The mean increase in body weight of the animals were 31.8±1.59, 33.2±1.02, 32.8±1.24, 31.0±0.78, 31.80±1.50, for groups I, II, III, IV and V respectively. The weights difference per 100g observed after 60 days treatment were 17.04±0.76, 17.31±.72, 16.40±1.01, 16.46±0.84 and 16.54±0.71 for groups I, II, III, IV and V, respectively. The body weight changes observed between the groups were not statistically significant when compared to the control. The organ body weight ratio were as follows; the liver, 5.48±0.075, 5.76±0.087, 5.63±0.042, 5.70±0.047 and 5.58±0.70 for groups I, II, III, IV and V, respectively, the spleen had 0.58±0.014, 0.60±0.021, 0.60±0.008, 0.57±0.008 and 0.57±0.018 for groups I, II, III, IV and V respectively, while the kidney had 0.87±0.017, 0.83±0.016, 0.85±0.020, 0.85±0.013 and 0.85±0.020 for groups I, II, III, IV and V, respectively (Table 3). The organ body weight ratios were also not significantly different between the treatment groups and the control.

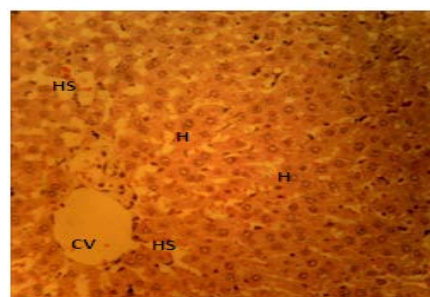
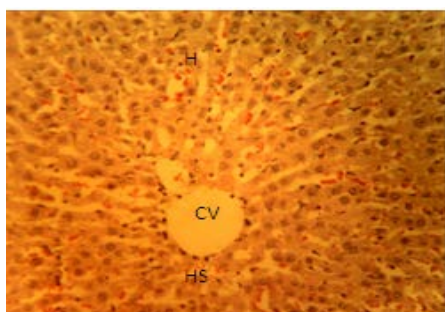
Haematological indices: The haematological indices observed after 60 days extract administration is as presented in Table 4 indicated no significant difference within and between the groups for all the haematological parameters measured.

Biochemical analysis: The Liver function test results obtained after 60 days of administration of the different

Table 5: Mean serum ALAT, ASAT, ALP and urea and electrolytes of wistar rats after 60 days of *C. papaya* seed extracts administration

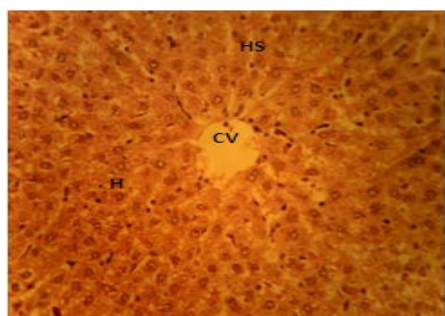
Groups parameters	I Control N/saline 2% Tween80	II Aqueous 100 mg/kg	III Aqueous 1000 mg/kg	IV Ethanolic 100 mg/kg	V Ethanolic 1000 mg/kg
Asat (IU/L)	21.6±2.54	18.6±0.68	21.2±1.24	18.0±0.55	21.200±1.72
Alat (IU/L)	49.8±3.32	49.0±5.40	51.6±7.28	49.2±7.87	51.8±9.71
Alp(IU/L)	47.8±3.37	59.4±5.72	59.6±3.74	66.2±3.65	60.6±4.11
Urea	29.8±1.46	28.8±1.89	29.4±2.58	27.6±2.42	29.0±2.67
Sodium	65.6±1.37	70±2.06	68.6±1.12	66.8±0.97	65.8±2.42
Potassium	2.6±0.51	2.6±0.51	3.4±0.40	2.4±0.51	2.6±0.4
Chloride	0.8±0.37	1.4±0.25	1.4±0.25	1.2±0.37	1.6±0.25

N per group = 5; Data expressed as Mean±SEM

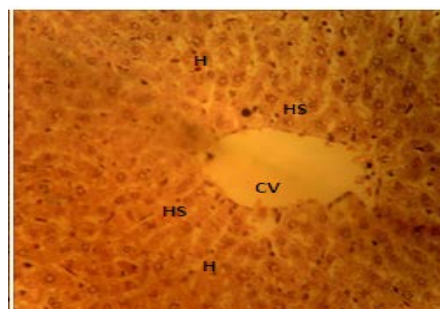


(a)

Fig. 1: Transverse section of the Liver of Wistar rats after 60-days oral administration 2ml/100g of N/S with 2% Tween80/day showing normal Central Vein (CV), Hepatocytes (H) and Hepatic Sinusoids (HS). H & E, X250

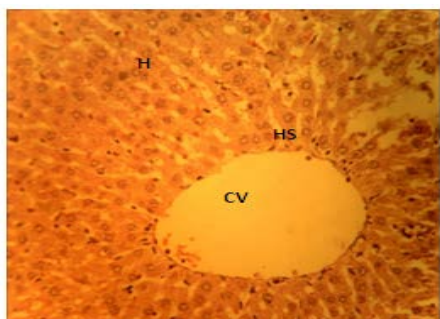


(a)



(b)

Fig. 3: Transverse section of the Liver of Wistar rats after 60-days oral administration of 100 mg/kg/day and 1000 mg/kg/day ethanolic seed extract of *C. papaya* respectively showing normal Central Vein (CV), Hepatocytes (H) and Hepatic Sinusoids (HS). H & E, X250



(b)

Fig. 2: Transverse section of the Liver of Wistar rats after 60-days of oral administration of 100 mg/kg/day and 1000 mg/kg/day of aqueous seed extract *C. papaya* showing normal Central Vein (CV), Hepatocytes (H) and Hepatic Sinusoids (HS). H & E, X250

extracts as presented in Table 5, it showed the differences that exist between the groups are statically insignificant. The results obtained are expressed in International Unit per Liter (IU/L) for serum Aspartate aminotransferase (AST), Alanine Aminotransferase (ALT) and Alkaline Phosphatase (ALP). The renal function test results after 60 days of extract administration is as shown in Table 5. The renal function test results obtained after 60 days of administration of the different extracts showed the differences that exist between the groups were not statically significant when compared to the control.

HISTOLOGICAL ANALYSIS

Histological analysis of the liver: Light microscopic examination of liver sections obtained from animals in

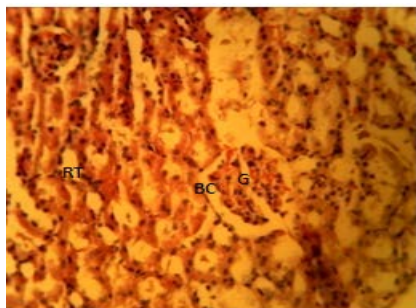
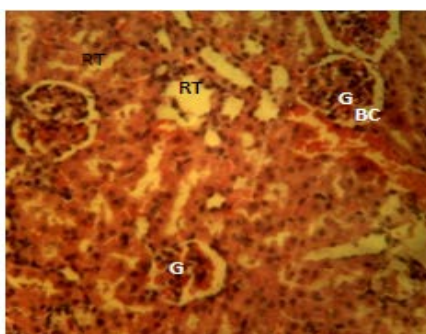
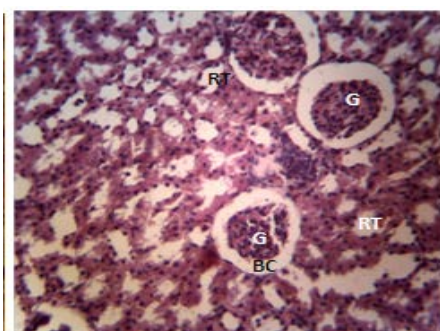


Fig. 4: Transverse section of the Kidney of Wistar rats after 60-days oral administration of 2ml/100g of N/S with 2% Tween80/day showing normal Glomerulus (G), Bowman's capsule (BC) and Renal Tubules (RT). H & E, X250



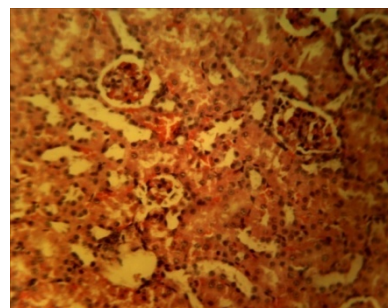
(a)



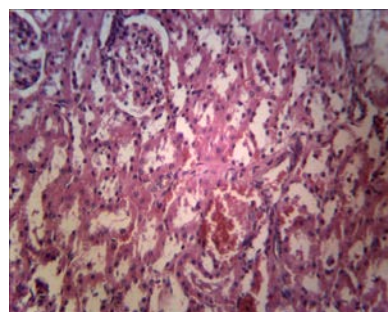
(b)

Fig. 5: Transverse section of the Kidney of Wistar rats after 60-days oral administration of 100 mg/kg/day and 1000 mg/kg/day aqueous seed extract of *C. papaya* showing normal Glomerulus (G), Bowman's capsule (BC) and Renal Tubules (RT). H & E, X250

both the acute and chronic study groups showed appearance of normal hepatic lobules consisting of branching and anastomosing plates of hepatic cells in between which are clear sinusoids showing branching and anastomosing pattern (Fig. 1 to 3b). The interlobular septa with the portal area consisting of branches of portal veins and hepatic arteries are also visible and clearly demarcated. Endothelial cells lining



(a)



(b)

Fig. 6: Transverse section of the Kidney of Wistar rats after 60-days of oral administration of 100 mg/kg/day and 1000 mg/kg/day ethanolic seed extract of *C. papaya* respectively showing normal Glomerulus (G), Bowman's capsule (BC) and Renal Tubules (RT). H & E, X250

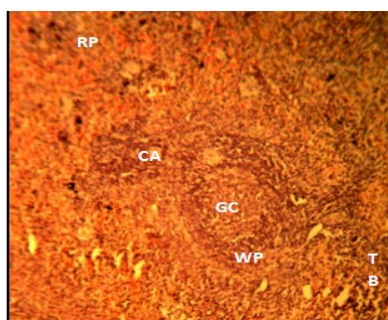
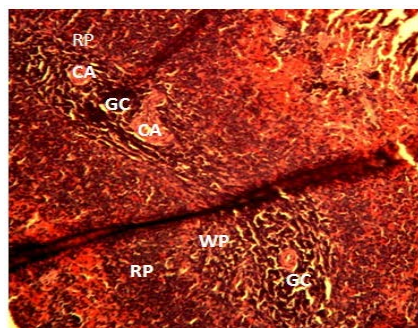
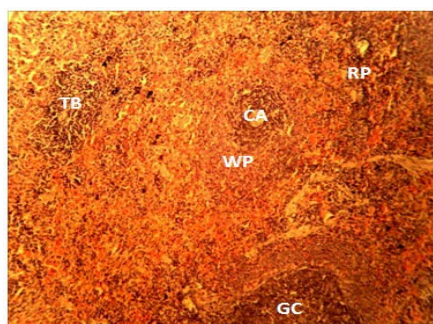


Fig. 7: Transverse section of the Spleen of Wistar rats after 60-days oral administration of 2ml/100gm of N/S with 2% Tween80/day showing normal Cytoarchitecture with Germinal centre (GC), Central artery (CA), white pulp (WP) red pulp (RP) and Trabeculae (TB). H & E, X100

the central vein and sinusoids were also visible in all the groups and red blood cells were also visible within the central vein and sinusoids. Also within the sinusoids were Kupffer cells. No necrosis or fatty changes were observed in all the section examined. Figure 1 represents control group while plates 2a to 3b represent sections from animals in the extract treated groups.

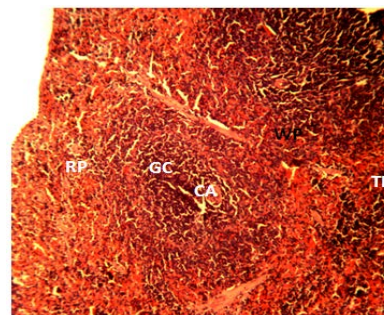


(a)

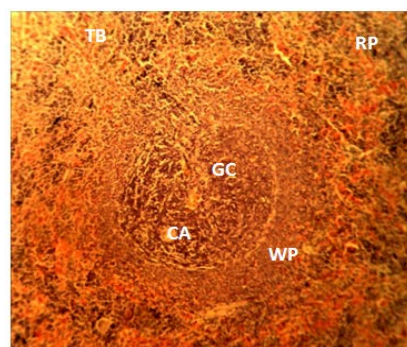


(b)

Fig. 8: Transverse section of the Spleen of Wistar rats after 60-days oral administration of 100 mg/kg/day and 1000 mg/kg/day aqueous seed extract of *C. papaya* respectively showing normal Cytoarchitecture with Germinal centre (GC), Central artery (CA), white pulp (WP) red pulp (RP) and Trabeculae (TB). H & E, X100 H & E, X100



(a)



(b)

Fig. 9: Transverse section of the Spleen of Wistar rats after 60-days oral administration of 100 mg/kg/day and 1000 mg/kg/day ethanolic seed extract of *C. papaya* respectively showing Cytoarchitecture with Germinal centre (GC), Central artery (CA), white pulp (WP) red pulp (RP) and Trabeculae (TB). H & E, X100

DISCUSSION

Histological analysis of the kidney: Light microscopic examination of kidney sections obtained from animals study groups showed normal renal cytoarchitecture. Sections obtained from the renal cortex of the animals from all the groups exhibits normal renal corpuscles and renal tubules which are surrounded by basement membrane. The glomeruli and Bowman's capsule all appear normal. The glomerular epithelium and the capsular space also appear normal for the control group (Fig. 4) and the treated groups' Fig. 5a to 6b as illustrated on the micrograph. Section of the medullary areas also exhibited normal collection of papillary ducts and ducts of loops of Henle.

Histological analysis of the spleen: Light microscopic examination of splenic sections obtained from animals study groups showed normal cytoarchitecture. Areas of red and white pulp along with central arteries were observed. The germinal centres were also visible along with the connective tissue trabeculae and all appeared normal for both control group Fig. 7 as well as for the treated groups Fig. 8a to 9b.

Assessment of haematological parameters can be used to determine the extent of deleterious effect of extracts on the blood of an animal. It can also be used to explain blood relating functions of a plant extract or its products (Yakubu *et al.*, 2007). Such analysis is relevant to risk evaluation as changes in the haematological system have higher predictive value for human toxicity, when the data are translated from animal studies for use in man (Olson *et al.*, 2000). According to Kohnke (2009), blood tests can also be used to determine the dehydration state, degree of anaemia, infection and immune challenge, physical stress as well as metabolic conditions. Some of these are undesirable effects that may be attributable to xenobiotics such as plant extracts. The result of this study showed that, the levels of RBC, Hb, PCV and WBC (Lymphocytes, neutrophils, monocytes, eosinophils and basophils) at all the doses were not altered in doses and duration used, again this may suggest therefore, the extracts at doses was not toxicologically significant on these parameter. The absence of significant effect of the extract on RBC, Hb

and PCV, could also mean that neither the incorporation of haemoglobin into red blood cells nor the morphology and osmotic fragility of the red blood cells was altered (Adebayo *et al.*, 2005). The non-significant effect of the extract on the RBC may also be an indication that the balance between the rate of production and destruction of the blood corpuscles (erythropoiesis) was not altered. This shows that it is relatively safe when used for long term in both high and low doses as done in the study. However, a contrary result was obtained by Ikpeme *et al.* (2011), the outcome of their study showed ethanolic seed and leaf extracts to be a blood boosters as the increased both Hb and PCV after 30 days oral administration. Organ weight changes have long been accepted as a sensitive indicator of chemically induced changes to organs. In toxicological experiments, comparison of organ weights between treated and untreated groups of animals have conventionally been used to evaluate the toxic effect of the test study (Peters and Boyd, 1966; Pfeiffer, 1968). According to Bailey *et al.* (2004) analysis of organ weight in toxicology studies is an important endpoint for identification of potentially harmful effects of chemicals. An important requirement in toxicological experiments is the ability to assess the effects of xenobiotics on specific organs.

Organ weight can be the most sensitive indicator of an effect of an experimental compound, as significant differences in organ weight between treated and untreated (control) animals may occur in the absence of any morphological changes (Bailey *et al.*, 2004). In this study, there were no changes observed in gross examination of the organs of both control and treated groups. The liver and kidney and spleen body weight ratio of the Wistar rats in the treated groups compared favourably with those of the controls at all the doses of administration of the extracts investigated. This may imply that the extract did not affect the secretory ability of the organs (Schmidt *et al.*, 2007). It is also possible that the extract did not cause any cellular constriction and/or inflammation of the organs which would have resulted in swelling and increase in weight (Schmidt *et al.*, 2007). This finding is corroborated by the histological findings which did not show any pathological changes in the liver kidneys and spleen of the treated animals.

The result of the renal function test indicated that none of the assayed parameters was significantly different from the control group. According to Schmidt *et al.* (2007) it may imply that the extract did not affect the secretory ability of the organs and the homeostatic function of the kidney is still intact. It can thus be said that the different extracts are not nephrotoxic. Serum enzyme measurements are valuable tool in clinical diagnosis, providing information on the effect and nature of pathological damage to any tissue (Wills, 1985). Therefore, the increase in serum Alanine aminotransferase (ALT), alkaline phosphatase and

Aspartate aminotransferase (AST) activities may indicate liver tissue damage probably by altered cell membrane permeability leading to the leakage of the enzymes from the tissues to the serum. Alanine and aspartate aminotransaminases are considered to be sensitive indicators of hepatocellular damage and within limit can provide a quantitative evaluation of the degree of damage to the liver (Al-Habori *et al.*, 2002). In the study all three enzymes were assayed for and where all within normal range and did not significantly differ from the control group, it could there for be interpreted that the extract was not injurious to the hepatocytes and the secondary organs which produce some of these enzymes.

In conclusion, this study has been able to establish that the Aqueous and Ethanolic extract of *C. papaya* of the homestead variety is non toxic in Wistar rats following chronic oral administration. The result of the renal function test has also established that the extract lacks nephrotoxic property at 100 and 1000 mg/kg body weights in chronic administration. The result of the liver function test has also established that the extract lacks hepatotoxicity property at 100 and 1000 mg/kg body weights in chronic administration. Its consumption in various forms for medicinal purposes maybe harmless to the various organs and tissues studied.

REFERENCES

- Adebayo, J.O., A.A. Adesokan, L.A. Olatunji, D.O. Buoro and A.O. Soladoye, 2005. Effect of Ethanolic extract of *Bougainvillea spectabilis* leaves on haematological and serum lipid variables in rats. *Biochemistry*, 17: 45.
- Al-Habori, M., A. Al-Aghbari, M. Al-Mamary and M. Baker, 2002. Toxicological evaluation of *Catha edulis* leaves. A long term feeding experiment in animals. *J. Ethnopharmacol.*, 83: 209-17.
- Bailey, S.A., R.H. Zidell and R.W. Perry, 2004. Relationship between organ weight and body/brain weight in the rat: What is the best analytical end point? *Toxicol. Pathol.*, 32(4): 448-66.
- Farnsworth, N.R., O. Akelere, A.S. Bingel, D.D. Soejarto and Z. Guo, 1985. Medicinal plants in therapy. *Bull. World Health Org.*, 63: 965-981.
- Ikpeme E.V., U.B. Ekaluo, M.E. Kooffreh and O. Udensi, 2011. Phytochemistry and haematological potential of ethanol seed leaf and pulp extracts of *Carica papaya* (Linn.). *Pakist. J. Biol. Sci.*, 14: 408-411.
- Kohnke, J., 2009. Blood Counts A Practical Guide to Common Problems. Retrieved from: [http:// www.kohnkesown.com/bloodcounts](http://www.kohnkesown.com/bloodcounts).
- Krishna, K.L., M. Paridhavi and J.A. Patel, 2008. Review on nutritional, medicinal and pharmacological properties of papaya (*Carica papaya* Linn.) *Indian J. Nat. Prod. Res.*, 7(4): 364-373.

- Mojica-Henshaw, M.P., A.D. Francisco, F. De Guzman and X.T. Tingo, 2003. Possible immunomodulatory actions of *Carica papaya* seed extract. *Clin. Hemorheol. Micro.*, 29: 219-229.
- Nester, E., E.E. Roberts, N.N. Pearsall and D.C. Anderson, 1998. *Microbiology: A Human Perspective*. 2nd Ed., Mc Gram Hill Co., U.S.A., pp: 475-657.
- OECD (Organization for Economic Co-operation and Development), 2003. Report No. 5 (February 2003). OECD, Paris, France.
- Olson, H., G. Betton, D. Robinson, K. Thomas, A. Monro, G. Kolaja, P. Lilly, J. Sanders, G. Sipes, W. Bracken, M. Dorato, K. Van Deun, P. Smith, B. Berger and A. Heller, 2000. Concordance of the toxicity of pharmaceuticals in humans and in animals. *Regul. Toxicol. Pharmacol.*, 32: 56-67.
- Peters, J.M. and E.M. Boyd, 1966. Organ weights and water levels of the rat following reduced food intake. *J. Nutr.*, 90(4): 354-60.
- Pfeiffer, C.J., 1968. A mathematical evaluation of the thymic weight parameter. *Toxicol. Appl. Pharmacol.*, 13(2): 220-227.
- Saxena, M.J., 2001. Relevance of herbs in improving health index of livestock animals. *Proceedings of 38th Congress of Nigerian Veterinary Medical Association*, Topo, Badagry, pp: 14-16.
- Schmidt, B.M., N. Ilic, A. Poulev and I. Raskin, 2007. Toxicological evaluation of a chicory root extract. *Food Chem. Toxicol.*, 45: 1131-1139.
- Silva, T.D., 1997. Medicinal Plants for Forest Conservation and Health Care: Industrial Utilization of Medicinal Plants in Developing Countries. In: Bodeker, G., K.K.S. Bhat, J. Burley and P. Vantomme (Eds.), *Global Initiative for Traditional Systems (gifts) of Health*. FAO (Non-wood Forest Products 11), Rome, pp: 34-44.
- Sofowora, E.A., 1985. *Medicinal Plants and Traditional Medicine in Africa*. 1st Edn., John Wiley and Sons, New York, pp: 5-8.
- Trease, G.E. and W.E. Evans, 1989. *Pharmacognosy*, 13th Edn., Baillere and Tyn dal, London.
- Villegas, V.N., 1997. Papaya (*Carica papaya*). In: Verheji, E.W.M. and R.E. Coronel (Eds.), *Edible Fruits and Nuts*. Wageningen University, Wageningen, Netherlands, 2: 108-11.
- Wills, D.E., 1985. *Biochemical Basis of Medicine*. 3rd Edn., John Wright and Sons Ltd., Bristol, England, pp: 267-268.
- Yakubu, M.T., M.A. Akanji and A.T. Oladiji, 2007. Haematological evaluation in male albino rats following chronic administration of aqueous extract of *Fadogia agrestis* stem. *Pharmacog. Mag.*, 3(9): 34-38.